

A Proposal for Standardizing Restenosis Patterns of Femoropopliteal Artery Disease

By Lawrence A. Garcia, MD

Peripheral artery disease is a common disorder, affecting over 200 million people worldwide.¹ Within this context, the femoropopliteal artery remains a common culprit of lifestyle-limiting claudication.² Although endovascular intervention of the femoropopliteal artery has become the preferred initial therapy for lifestyle-limiting claudication compared to surgery,³ no single endovascular technology has emerged as a first-line therapy. Despite the spectrum of available endovascular therapies, restenosis remains the major limitation of all modalities regardless of device technology.⁴ Additionally, the morphology of restenosis may in fact be similar or distinct among therapies, as reported by some investigators.⁵ These differences in restenosis patterns may therefore provide clues to health care providers when determining treatment strategies for patients. However, comparing success (eg, freedom from reintervention rate or patency rate) across therapies is difficult due to the variability of study design, metric definitions, subjects enrolled, lesion morphology, and follow-up. Importantly,

other groups have introduced systems for describing device failure (restenosis within the target lesion), albeit specific to stent-based therapies.^{6,7} However, given the myriad of devices and strategies currently available that are not strictly reliant on permanent implants for femoropopliteal artery disease treatment, stent-based systems of restenosis classification are limited in their applicability because they cannot characterize restenosis patterns of these non-stent treatments. Thus, describing failure modes of therapies remains problematic in the absence of a unifying nomenclature for classifying restenosis morphology independent of treatment modality. However, detailing a classification system for restenosis regardless of device used at the index procedure may provide an adequate level of unification across device technologies.

To confront this challenge, eight experts in the treatment of femoropopliteal artery disease collaborated with an industry partner (Medtronic plc) to review restenosis patterns across an assortment of treatment modalities in core lab–adjudicated trials (both registries and randomized trials) and propose a device-agnostic classification system. Eight clinical trial and registry cohorts totaling 2,376 patients were included in the development of this classification system, including 403 imaging studies corresponding to the pooled target lesion revascularizations. Treatment modalities examined as part of this study included percutaneous transluminal angioplasty (IN.PACT SFA control arm⁸), drug-coated balloon angioplasty (IN.PACT SFA study device arm⁸ and IN.PACT Global interim follow-up⁹), directional atherectomy (DEFINITIVE LE above-knee cohort¹⁰), directional atherectomy followed by drug-coated balloon angioplasty (DEFINITIVE AR directional atherectomy antirestenosis therapy cohort¹¹), and nitinol bare-metal stent (Complete SE SFA,¹² DURABILITY II,¹³ and IN.PACT Global baseline in-stent restenosis cohort¹⁴). Angiographic studies from these trials were centralized at an angiographic core lab, which performed two roles: preparation of non-stent cases for evaluation and application of the final scoring system to evaluable cases of the 403 imaging studies.

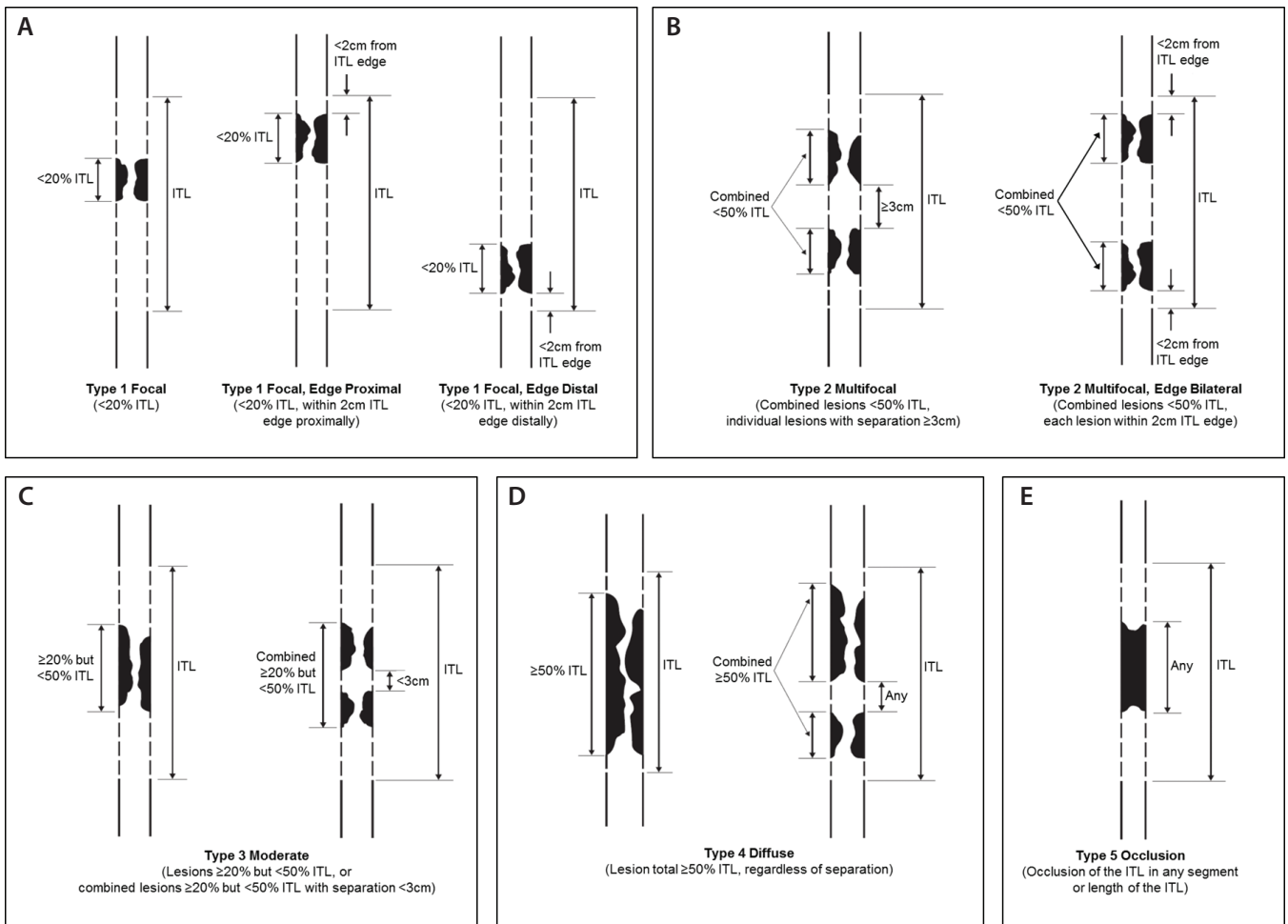


Figure 1. Proposed patterns of restenosis classification system.

Unlike stent-based classification systems previously introduced,^{6,7} a classification system that includes non-in-stent restenosis would be complicated in that the index treated arterial length may not reliably be determined from angiographic images. Hence, the angiographic core lab determined the index treated length (ITL) of non-stent cases by evaluating available corresponding baseline images. Once the ITLs were determined, they were mapped to their respective restenosis patterns observed during the revascularization procedures. In this manner, restenosis patterns of non-stent modalities were evaluated with respect to their ITLs in a similar manner to the in-stent restenosis patterns where implants exist. Therefore, **the mapping process employed by the**

core lab allowed restenosis scoring of any treatment modality, including both stent and non-stent therapies.

With both in-stent and non-stent restenosis patterns prepared for evaluation, the panel reviewed a series of restenosis cases and determined that themes of restenosis morphologies emerged that could be categorized based on easily identified characteristics (eg, occlusions vs restenotic lesions, single vs multilesion restenoses, and length of restenosis within the ITL). Considering these observations, the restenosis pattern classification system was constructed around five types of restenosis: focal lesions consisting of lengths < 20% of the ITL, including proximal and distal edge patterns;

multifocal lesions combining to < 50% of the ITL, including bilateral edge patterns; moderate length lesions consisting of lengths < 50% of the ITL; diffuse lesions totaling ≥ 50% of the ITL regardless of focal or multifocal nature; and occlusions. Importantly, to include only clinically relevant restenosis patterns in the classification system, a qualifying lesion was required to exhibit a stenosis ≥ 50% of the reference vessel diameter. Additionally, any lesion observed in the revascularization images that were outside the ITL was excluded from evaluation. Figure 1 demonstrates the proposed patterns of restenosis classification system.

Once developed, the panel applied this classification system to a pilot series of 32 cases that were then scored by the angiographic core lab blinded to the panel's scores. The results indicated a high degree of validation with the expert panel; one case was deemed unevaluable due to incomplete imaging, three cases were disqualified for not meeting the ≥ 50% diameter stenosis requirement, and the remaining 28 cases scored identically. These outcomes validated the reproducibility of the classification system employed by independent scoring groups and enabled moving this effort into evaluating the full cohort of 403 imaging studies.

Although the concept of employing a classification system for arterial restenosis patterns has been reported by others,^{6,7} the primary limitation of such classification systems is the applicability to in-stent restenosis only, thereby excluding other modalities common to the treatment of femoropopliteal artery disease. Because **this endeavor sought to address limitations of existing classification systems by proposing a device-agnostic classification tool** that could be applied by both individual operators and core labs alike, an angiographic core lab was included during the development that enabled evaluation of both in-stent and non-stent restenosis patterns. The resulting five-category system reflects restenosis patterns commonly encountered in femoropopliteal artery disease treatment and subsequent failure. It is hoped that the expanded applicability and additional descriptive value rendered by the proposed classification system will unify observations as they

relate to treatment outcomes and facilitate operator treatment strategies.

1. Fowkes FG, Rudan D, Rudan I, et al. Comparison of global estimates of prevalence and risk factors for peripheral artery disease in 2000 and 2010: a systematic review and analysis. *Lancet*. 2013;382:1329-1340.
2. Schillinger M, Minar E. Claudication: treatment options for femoropopliteal disease. *Prog Cardiovasc Dis*. 2011;54:41-46.
3. Conrad MF, Cambria RP, Stone DH, et al. Intermediate results of percutaneous endovascular therapy of femoropopliteal occlusive disease: a contemporary series. *J Vasc Surg*. 2006;44:762-769.
4. Otsuka F, Nakano M, Sakakura K, et al. Unique demands of the femoral anatomy and pathology and the need for unique interventions. *J Cardiovasc Surg (Torino)*. 2013;54:191-210.
5. Schmidt A, Piorkowski M, Werner M, et al. First experience with drug-eluting balloons in infrapopliteal arteries: restenosis rate and clinical outcome. *J Am Coll Cardiol*. 2011;58:1105-1109.
6. Mehran R, Dangas G, Abizaid AS, et al. Angiographic patterns of in-stent restenosis: classification and implications for long-term outcome. *Circulation*. 1999;100:1872-1878.
7. Tosaka A, Soga Y, Iida O, et al. Classification and clinical impact after femoropopliteal stenting. *J Am Coll Cardiol*. 2012;59:16-23.
8. Tepe G, Laird J, Schneider P, et al. Drug-coated balloon versus standard percutaneous transluminal angioplasty for the treatment of superficial femoral popliteal peripheral artery disease: 12-month results from the IN.PACT SFA randomized trial. *Circulation*. 2015;131:495-502.
9. Ansel G. The IN.PACT global clinical study: First report of prospective outcomes using the IN.PACT Admiral DCB in an unrestricted, real world environment. Presented at: TCT; September 2014; Washington, DC..
10. McKinsey JF, Zeller T, Rocha-Singh KJ, et al. Lower extremity revascularization using directional atherectomy: 12-month prospective results of the DEFINITIVE LE study. *J Am Coll Cardiol Interv*. 2014;7:923-933.
11. Zeller T. DEFINITIVE AR: a pilot study of antirestenosis treatment. 12-month results: directional atherectomy followed by a paclitaxel-coated balloon to inhibit restenosis and maintain vessel patency. Presented at: Vascular InterVentional Advances (VIVA); 2014; Las Vegas, Nevada.
12. Laird J. The Complete SE SFA trial. Presented at: ISET; January 2012; Hollywood, Florida.
13. Matsumura JS, Yamanouchi D, Goldstein JA, et al. The United States study for evaluating endovascular treatments of lesions in the superficial femoral artery and proximal popliteal by using the Protégé Everflex nitinol stent system II (DURABILITY II). *J Vasc Surg* 2013;58:73-83.
14. Brodmann M. Drug-coated balloon treatment for patients with lifestyle limiting claudication: new insights from the IN.PACT global study in-stent restenosis imaging cohort. *Vascular InterVentional Advances (VIVA)*; November 2015; Las Vegas, Nevada.

Lawrence A. Garcia, MD

Section of Interventional Cardiology and Peripheral Interventions

**St. Elizabeth's Medical Center
Boston, Massachusetts**

lawrence.garcia@steward.org

Disclosures: Receives grant/research support from Abbott Vascular, Medtronic; consultant to Medtronic, Boston Scientific Corporation, Abbott Vascular; equity in Arsenal, Primacea, TissueGen, CV Ingenuity, Spirox, Scion Cardiovascular, Syntervention, Essential Medical; and ownership in Innovation Vascular Partners, Consulting.