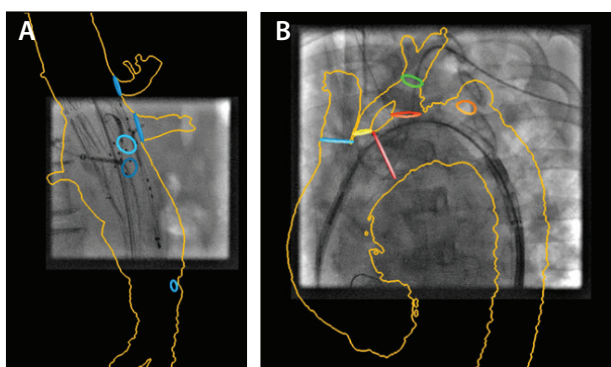


# Image Fusion for Vascular Procedures

The impact and continuing development of image fusion for planning and guiding vascular repair.

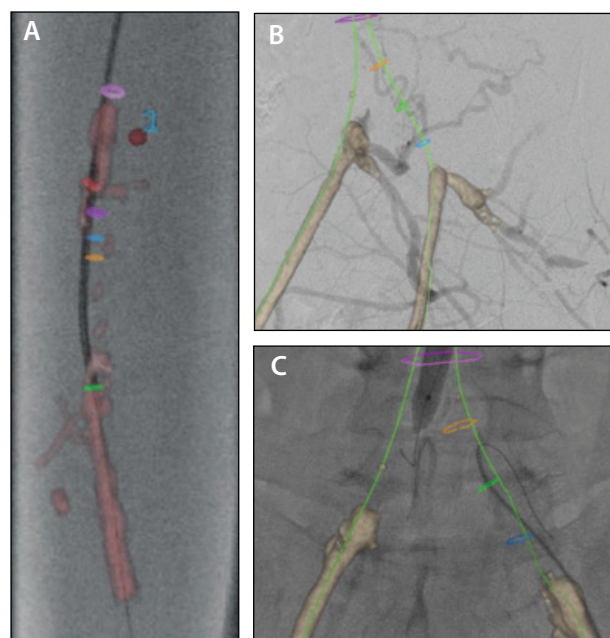
**BY STÉPHAN HAULON, MD, PhD; DOMINIQUE FABRE, MD, PhD; JUSTINE MOUGIN, MD; PHILIPPE CHARBONNEAU, MD; ANTOINE GIRAULT, MD; MAXIME RAUX, MD; AND YANN GOUËFFIC, MD, PhD**

Imaging technology advancements over the past decade have radically changed vascular surgery practice, accelerating the trend from an open to an endovascular approach and supporting the development of increasingly complex minimally invasive procedures in hybrid operating rooms (HORs). Among advanced imaging features available in modern HORs, image fusion consists of overlaying clinical information from multiple image types and modalities, typically vascular anatomy from preoperative CT/magnetic resonance or preoperative cone-beam CT (CBCT) over live fluoroscopy, providing a continuous three-dimensional (3D)/two-dimensional (2D) overlay for augmented live guidance.



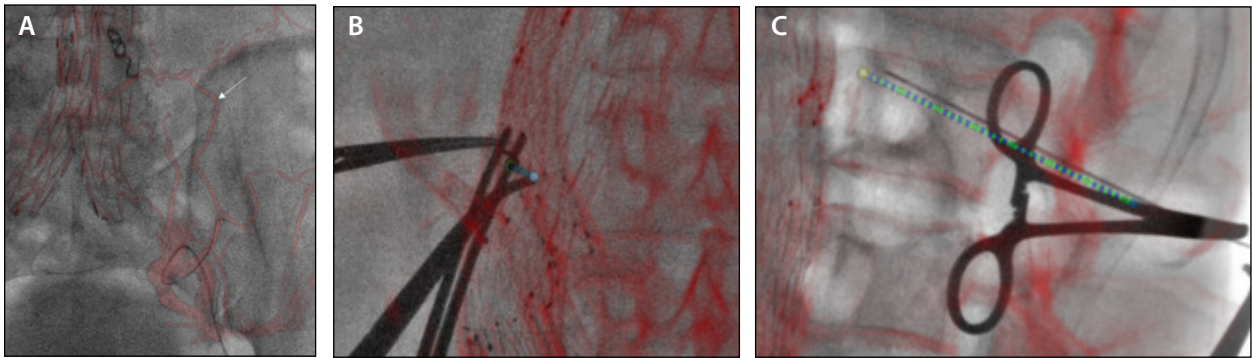
**Figure 1.** EVAR guided by image fusion (Discovery IGS 740 HOR equipped with EVAR Assist, GE Healthcare). The 3D model associates the aortic silhouette with the landmarks positioned by the operator. Graft landing zone and target visceral (A) and supra-aortic (B) vessel ostia are identified with planning circles, with optimal gantry angulations for their selection stored during planning and recalled from tableside for guidance. Several rendering modes and opacity options are available to display landmarks without obscuring live fluoroscopic visibility. Image fusion also allows gantry and table positioning without the use of x-ray, further reducing radiation exposure.

Although several publications have reported the value of image fusion in guiding endovascular aneurysm repair (EVAR), thoracic EVAR, and fenestrated/branched EVAR,<sup>1-11</sup> similar benefits have been suggested in aortic dissection repair cases,<sup>12-14</sup> aortic arch repair (Figure 1),<sup>15,16</sup> aortoiliac and lower limb chronic total occlusion recanalization (Figure 2),<sup>17,18</sup> carotid stenting,<sup>19,20</sup> and type II endoleak embolization (Figure 3).<sup>21</sup>



**Figure 2.** Endovascular recanalization of the superficial femoral (A) and iliac (B, C) arteries guided by image fusion. Vessel centerline and lumen semiautomatically extracted from the preoperative CT (Vessel Assist, GE Healthcare), with manual adjustment of the recanalization path through the occlusion. Planning lines defined on CT to provide lumen boundaries, avoiding calcifications, and planned stent position. Calcifications extracted from CT are used as landmarks for accurate registration.

Courtesy of Nicolas Loidic, MD.



**Figure 3.** Transarterial approach to type II endoleak embolization. Sac-feeding vessel(s) (arrow) identified on preoperative CT and overlaid on live fluoroscopy to facilitate catheterization (A). Translumbar approach with 3D needle trajectory planned on CT/CBCT fusion and overlaid on live fluoroscopy for guidance (Needle Assist, GE Healthcare) (B, C). Accurate fusion enabled by endograft-based registration from tableside. Other approaches, such as transcaval and transgraft, are less common but also benefit from image fusion.

## EVOLUTION OF FUSION IMAGE TECHNOLOGY

Originally simply based on a volume rendering of the vascular anatomy, image fusion has evolved toward a more elaborate 3D model that integrates the surgeon's operating plan. This strategy can include planning for proximal and distal stent graft landing zones, ostia of target vessels with optimal gantry angulations for catheterization (Figure 1 shows the lateral view for superior mesenteric artery catheterization), dissected aorta true and false lumen entry tears, and occluded vessel centerline and lumen boundaries along the planned recanalization pathway (Figure 2). Thus, standard 2D fluoroscopy is reshaped into a live augmented fluoroscopy environment.

Beyond enhancing operator comfort and confidence, adoption of image fusion into regular practice significantly impacts technical success by helping surgeons operate per plan in deploying devices with greater accuracy while reducing procedure time, operator and patient radiation dose, and contrast media volume.<sup>1-21</sup> Image fusion thus benefits all cases, whether simple or complex.

Although earlier iterations of fusion required 3D/3D registration using a preoperative CBCT, fusion has become easier to use, now only requiring registration on two 2D views, with full control from tableside. With the initial registration based on bones and calcifications, registration typically needs fine-tuning from tableside based on angiographic runs. Ease-of-use improvements along with step-by-step guided workflows have reduced the operator learning curve and facilitated standardization between sites.<sup>2</sup> Further automation to simplify workflows, as well as more evidence

of clinical outcomes, are expected to lead to wider adoption of the technology by the community and further-reaching benefits to patients.

## FUTURE DIRECTIONS

Several challenges remain to be tackled over the next decade. Image fusion should aim to compensate for vascular distortion, especially of the iliac and the target visceral arteries,<sup>22-24</sup> by including real-time or simulated aortic deformation due to stiff endovascular material insertion in the 3D overlaid model. Fusion inaccuracies due to arm position differences between CT and the live procedure, as well as cardiac and respiratory motion, should also be compensated for to improve guidance in arch repair cases.<sup>15</sup>

New technologies such as device electromagnetic or image-based live tracking and other modalities such as 3D intravascular ultrasound may also offer new horizons,<sup>25-29</sup> possibly enhancing current image fusion technology into a contrast-free, radiation-free, dynamically and nonrigidly registered new guidance option. ■

1. Hertault A, Maurel B, Sobocinski J, et al. Impact of hybrid rooms with image fusion on radiation exposure during endovascular aortic repair. *Eur J Vasc Endovasc Surg.* 2014;48:382-390.
2. Hertault A, Rhee R, Antoniou GA, et al. Radiation dose reduction during EVAR: results from a prospective multicenter study (the REVAR study). *Eur J Vasc Endovasc Surg.* 2018;56:426-433.
3. McNally MM, Scali ST, Feezor RJ, et al. Three-dimensional fusion computed tomography decreases radiation exposure, procedure time, and contrast use during fenestrated endovascular aortic repair. *J Vasc Surg.* 2015;61:309-316.
4. Stangenberg L, Shuja F, Carelsen B, et al. A novel tool for three-dimensional roadmapping reduces radiation exposure and contrast agent dose in complex endovascular interventions. *J Vasc Surg.* 2015;62:448-455.
5. Sailer AM, de Haan MW, Peppelenbosch AG, et al. CTA with fluoroscopy image fusion guidance in endovascular complex aortic aneurysm repair. *Eur J Vasc Endovasc Surg.* 2014;47:349-356.
6. Goudekting SR, Heimen SGH, Ünlü Ç, et al. Pros and cons of 3D image fusion in endovascular aortic repair: a systematic review and meta-analysis. *J Endovasc Ther.* 2017;24:595-603.
7. Tenorio ER, Oderich GS, Sandri GA, et al. Impact of onlay fusion and cone beam computed tomography on radiation exposure and technical assessment of fenestrated-branched endovascular aortic repair. *J Vasc Surg.* 2019;69:1045-1058.e3.

8. Tacher V, Lin M, Desgranges P, et al. Image guidance for endovascular repair of complex aortic aneurysms: comparison of two-dimensional and three-dimensional angiography and image fusion. *J Vasc Interv Radiol.* 2013;24:1698-1706.
9. Wermelink B, Willigendael EM, Smit C, et al. Radiation exposure in an endovascular aortic aneurysm repair program after introduction of a hybrid operating theater. *J Vasc Surg.* 2019;70:1927-1934.e2.
10. de Ruiter QMB, Reitsma JB, Moll FL, van Herwaarden JA. Meta-analysis of cumulative radiation duration and dose during EVAR using mobile, fixed, or fixed/3D fusion C-arms. *J Endovasc Ther.* 2016;23:944-956.
11. Martin-Gonzalez T, Hertault A, Maurel B, et al. Image fusion performed with noncontrast computed tomography scans during endovascular aneurysm repair. *J Vasc Surg Cases.* 2015;1:53-56.
12. Mirza AK, Tenorio ER, Karkkainen JM, et al. Technical video of endovascular repair of chronic post dissection thoracoabdominal aortic aneurysm using a five-vessel preloaded fenestrated-branched stent graft. *J Vasc Surg.* 2019;69:296-302.e1.
13. Spear R, Hertault A, Van Calster K, et al. Complex endovascular repair of postdissection arch and thoracoabdominal aneurysms. *J Vasc Surg.* 2018;67:685-693.
14. Kaladji A, Dumenil A, Castro M, et al. Endovascular aortic repair of a postdissecting thoracoabdominal aneurysm using intraoperative fusion imaging. *J Vasc Surg.* 2013;57:1109-1112.
15. Hertault A, Clough R, Modine T, et al. Does it/will it work: utility of fusion imaging for the aortic arch. *Endovasc Today.* 2016;15:72-74, 76.
16. Haulon S, Soler R, Watkins AC, et al. Endovascular arch replacement with an endoprosthesis with three inner branches. *Ann Cardiothorac Surg.* 2018;7:431-433.
17. Louis N, Durrleman N, Joyeux F, et al. Contribution of the circles of planning under 3D fusion of images to treat chronic arterial occlusions. *Ann Vasc Surg.* 2018;53:27-28.
18. Ierardi AM, Duka E, Radaelli A, et al. Fusion of CT angiography or MR angiography with unenhanced CBCT and fluoroscopy guidance in endovascular treatments of aorto-iliac steno-occlusion: technical note on a preliminary experience. *Cardiovasc Intervent Radiol.* 2016;39:111-116.
19. Myrcha P, Milek T, Wozniak W, et al. 3D-fusion-imaging-assisted carotid artery stenting is safe and feasible. *Int Angiol.* 2019;38:326-333.
20. Swerdlow NJ, Jones DW, Pothof AB, et al. Three-dimensional image fusion is associated with lower radiation exposure and shorter time to carotid cannulation during carotid artery stenting. *J Vasc Surg.* 2019;69:1111-1120.
21. Rhee R, Oderich G, Hertault A, et al. Multicenter experience in translumbar type II endoleak treatment in the hybrid room with needle trajectory planning and fusion guidance. *J Vasc Surg.* 2018;68:e12-e13.
22. Maurel B, Hertault A, Gonzalez TM, et al. Evaluation of visceral artery displacement by endograft delivery system insertion. *J Endovasc Ther.* 2014;21:339-347.
23. Gindre J, Bel-Brunon A, Rochette M, et al. Patient-specific finite-element simulation of the insertion of guidewire during an EVAR procedure: guidewire position prediction validation on 28 cases. *IEEE Trans Biomed Eng.* 2017;64:1057-1066.
24. Lessard S, Kauffmann C, Pfister M, et al. Automatic detection of selective arterial devices for advanced visualization during abdominal aortic aneurysm endovascular repair. *Med Eng Phys.* 2015;37:979-986.
25. Pearce BJ, Jordan WD. Using IVUS during EVAR and TEVAR: improving patient outcomes. *Semin Vasc Surg.* 2009;22:172-180.
26. Zanchetta M, Rigatelli G, Pedon L, et al. IVUS guidance of thoracic and complex abdominal aortic aneurysm stent-graft repairs using an intracardiac echocardiography probe: preliminary report. *J Endovasc Ther.* 2003;10:218-226.
27. von Segesser LK, Marty B, Ruchat P, et al. Routine use of intravascular ultrasound for endovascular aneurysm repair: angiography is not necessary. *Eur J Vasc Endovasc Surg.* 2002;23:537-542.
28. Hoshina K, Kato M, Miyahara T, et al. A retrospective study of intravascular ultrasound use in patients undergoing endovascular aneurysm repair: its usefulness and a description of the procedure. *Eur J Vasc Endovasc Surg.* 2010;40:559-563.
29. Manstad-Hulaas F, Tangen GA, Dahl T, et al. Three-dimensional electromagnetic navigation vs. fluoroscopy for endovascular aneurysm repair: a prospective feasibility study in patients. *J Endovasc Ther.* 2012;19:70-78.

### Stéphan Haulon, MD, PhD

Aortic Centre, Vascular Surgery  
Fondation Saint Joseph Marie Lannelongue  
Paris, France  
s.haulon@hml.fr

*Disclosures: Consultant to GE Healthcare.*

### Dominique Fabre, MD, PhD

Aortic Centre, Vascular Surgery  
Fondation Saint Joseph Marie Lannelongue  
Paris, France

*Disclosures: None.*

### Justine Mougin, MD

Aortic Centre, Vascular Surgery  
Fondation Saint Joseph Marie Lannelongue  
Paris, France

*Disclosures: None.*

### Philippe Charbonneau, MD

Aortic Centre, Vascular Surgery  
Fondation Saint Joseph Marie Lannelongue  
Paris, France

*Disclosures: None.*

### Antoine Girault, MD

Aortic Centre, Vascular Surgery  
Fondation Saint Joseph Marie Lannelongue  
Paris, France

*Disclosures: None.*

### Maxime Raux, MD

Aortic Centre, Vascular Surgery  
Fondation Saint Joseph Marie Lannelongue  
Paris, France

*Disclosures: None.*

### Yann Gouëffic, MD, PhD

Aortic Centre, Vascular Surgery  
Fondation Saint Joseph Marie Lannelongue  
Paris, France

*Disclosures: None.*